

## CLINICAL AND HISTOPATHOLOGICAL ASPECTS OF ANEURYSMAL DERMATOFIBROMA IN THE CONTEXT OF NON-HODGKIN LYMPHOMA

ANDREEA-RALUCA SZŐKE\*, MARIA-CĂTĂLINA POPELEA\*, MIHAELA COVACIUC\*,  
CARMEN BEATRICE PATRICIA FRICIU\*\*, SILVIU-HORIA MORARIU\*\*\*,\*\*\*\*,  
OVIDIU S. COTOI\*,\*\*\*\*,<sup>1</sup>

### Summary

**Introduction:** Aneurysmal dermatofibroma is a benign mesenchymal tumor of the skin, representing < 2% of all histologic types of dermatofibromas, with a predilection for women and mostly occurring on the legs. The etiology is still unknown, but the association with local trauma and insect bites suggests a reactive process. However, recent cytogenetic data and multiple dermato-fibromas in immunosuppressed population are arguments for a neoplastic origin.

**Case report:** A 71-year-old woman presented with an erythematous and ulcerated nodule of 14 mm in diameter on the left calf following an insect bite 5 years ago. The lesion was treated with local antibiotics and antihistaminic drugs, but with no favorable results. The medical history of the patient revealed insulin-dependent diabetes mellitus, arterial hypertension, and ischemic heart disease. In 2009, the patient was diagnosed with non-Hodgkin's lymphoma and treated with standard chemotherapy until 2016. The histopathological examination of the excisional biopsy of the left calf nodule demonstrated an aneurysmal dermato-fibroma, characterized by cleft-like hemorrhagic spaces within the dermis, that mimic vessels but lack an endothelial lining. The composite lesional cells were seen in fascicles and storiform arrangement, with no cytonuclear atypia. The Grenz zone (sparing of the superficial papillary dermis) was observed. Perls' Prussian Blue staining highlighted in green intra- and extracellular hemosiderin depositions.

**Conclusions:** The particularity of the case is the presence of both possible and in opposition etiological factors - insect bite and immunosuppression, in the context of non-Hodgkin's lymphoma, in an old woman patient. Complete evaluation and multidisciplinary approach of these patients is necessary, considering the aneurysmal histologic subtype of the dermatofibroma, associated with a higher risk of local recurrence, and the possibility of the appearance of multiple dermatofibromas in immunosuppressed populations.

**Keywords:** aneurysmal dermatofibroma, immuno-suppression, insect bites, non-Hodgkin's lymphoma.

Received: 12.05.2021

Accepted: 16.06.2021

\* Department of Pathology, Mureş County Clinical Hospital, Târgu-Mureş, Romania.

\*\* Department of Plastic and Reconstructive Microsurgery, Mureş County Clinical Hospital, Târgu-Mureş, Romania.

\*\*\* Dermatology Clinic, Mureş Clinical County Hospital, Târgu-Mureş, Romania.

\*\*\*\* Department of Dermatology, 'George Emil Palade' University of Medicine, Pharmacy, Science, and Technology, Târgu-Mureş, Romania

\*\*\*\*\* Department of Pathophysiology, 'George Emil Palade' University of Medicine, Pharmacy, Science, and Technology, Târgu-Mureş, Romania.

<sup>1</sup> Contributed equally to this work.

## Introduction

Dermatofibroma (fibrous histiocytoma, DF) represents one of the most common benign cutaneous soft tissue tumors, which can arise at any age, but is more frequent in the third and fourth decades of life. It shows a slightly female predominance, and the majority of lesions are located on the legs, followed by arms and trunk [1,2].

The pathogenesis is still unknown, being controversial if dermatofibroma is a reactive or neoplastic condition. The lesions were reported to arise after local trauma and insect bites, these associations suggesting a reactive pathomechanism [3]. Recently, cytogenetic data revealed an alteration of protein C kinase isoforms activity and chromosomal abnormalities, which are arguments for a neoplastic origin [4,5]. Moreover, disseminated dermatofibromas are associated with immunosuppressive disorders like HIV, autoimmune diseases, and immunosuppressive drugs [6].

The clinical features of fibrous histiocytoma are those of an isolated, well-circumscribed, symmetrical, and asymptomatic papular/nodular lesion, typically  $\leq 1$  cm in diameter. The overlying skin may be erythematous or hyperpigmented with brown borders [7].

Dermatofibromas have heterogeneous histopathological aspects, with multiple variants

described. The aneurysmal variant represents less than 2% of fibrous histiocytomas and it is characterized by usually rapid growth, due to intralesional hemorrhage, and clinical confusion with a vascular tumor [8.] Furthermore, this variant presents a higher risk of local recurrence and, rarely, it can metastasize in regional lymph nodes or lungs [9].

The article aims to describe this rare aneurysmal subtype of fibrous histiocytoma in a patient with non-Hodgkin's lymphoma, a lesion frequently misdiagnosed by clinicians as a malignant tumor, with a higher risk of recurrence and metastasis, in comparison with common histological dermatofibromas.

## Case report

A 71-year-old woman was admitted to the Dermatology Department for an erythematous and ulcerated nodule of 14 mm diameter on the left calf, following an insect bite in 2016. The lesion was treated with local antibiotics and antihistaminic drugs, but with no favorable results, moreover, the lesion had slow enlarging in size over the last 5 years. She reported bleeding in the last 3 days, but no pain unless firmly palpated.

The patient's medical history revealed insulin-dependent diabetes mellitus, arterial hypertension, and ischemic heart disease. Also,

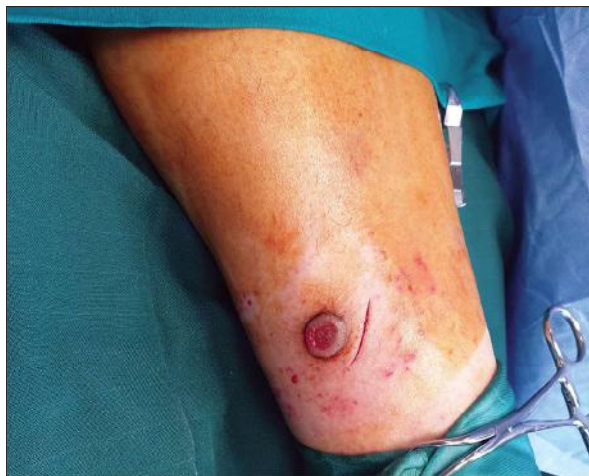

Figure 1. Clinical aspect of aneurysmal dermatofibroma. Excisional biopsy.

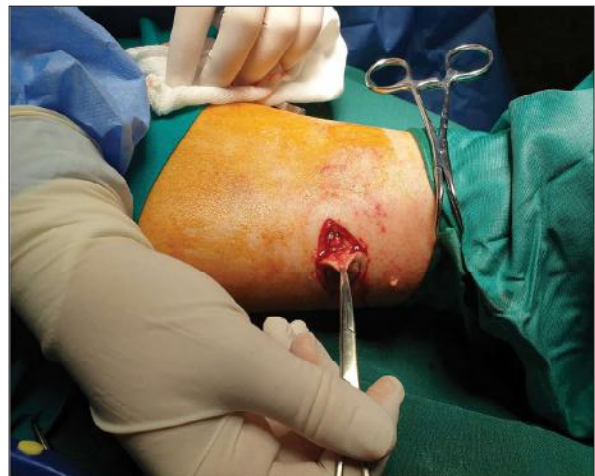

Figure 2. Clinical aspect of aneurysmal dermatofibroma. Excisional biopsy.

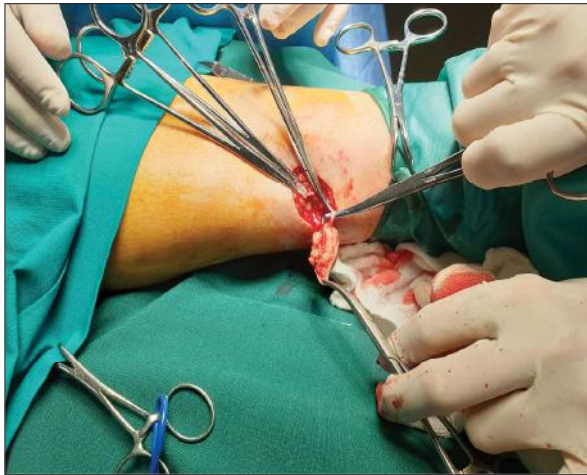

Figure 3. Clinical aspect of aneurysmal dermatofibroma. Excisional biopsy.

in 2009, the patient was diagnosed with non-Hodgkin's lymphoma, treated with standard chemotherapy until 2016.

The general clinical examination demonstrated a good current health status, clear lung sounds, with equal aeration bilaterally, without rales. On evaluation, the patient was normotensive, with sinus rhythm, normal heart rate, and no detectable murmur. The dermatological evaluation revealed a well-perfused skin, good turgor, with no other macroscopic lesions, except the nodule described previously. There was no family history of cutaneous malignancy and no regional adenopathy was noted.

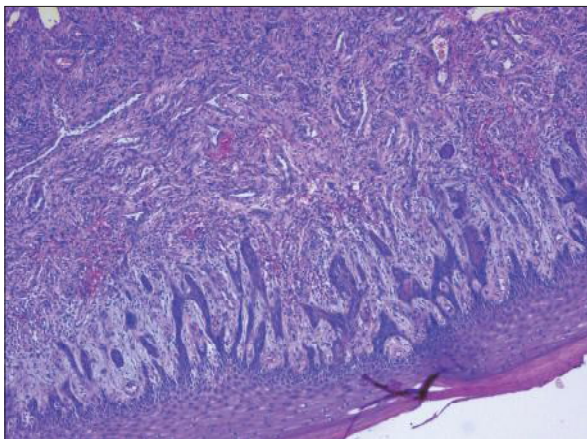


Figure 4. Histologic aspect of aneurysmal dermatofibroma. Hematoxylin-Eosin staining, x5.

An excisional biopsy of the nodule, in local anesthesia, was performed, which served as a treatment in the presented case. The ellipse of full-thickness skin and subcutaneous adipose tissue was measured 34x24x9 mm, with an overlying nodule of 14 mm in diameter.

The histopathological examination of the left calf nodule demonstrated a lesion centered in the mid-reticular dermis, with irregular cleft-like hemorrhagic spaces, that mimic vessels, but without an endothelial lining. The composite lesional cells were seen in storiform and fascicular patterns, with no cytonuclear atypia. At the periphery, collagen was trapped forming collagen balls. The Grenz zone (sparing of the superficial papillary dermis) was observed. Perls' Prussian Blue staining highlighted in green intra- and extracellular hemosiderin depositions. The epidermis overlying the lesion exhibited parakeratotic hyperkeratosis, with elongated rete ridges and acanthosis. The hypodermis was tumor-free and the perilesional skin appendages microscopically normal. The overall microscopic architecture in hematoxylin-eosin staining was consistent with the diagnosis of benign aneurysmal fibrous histiocytoma, excised in safety surgical margins.

As of this paper's submission, the surgical site healed and the patient will be reevaluated at 3 months.

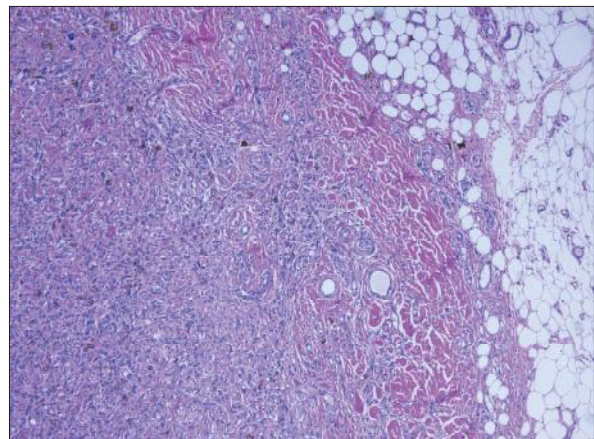


Figure 5. Histologic aspect of aneurysmal dermatofibroma. Hematoxylin-Eosin staining, x5.

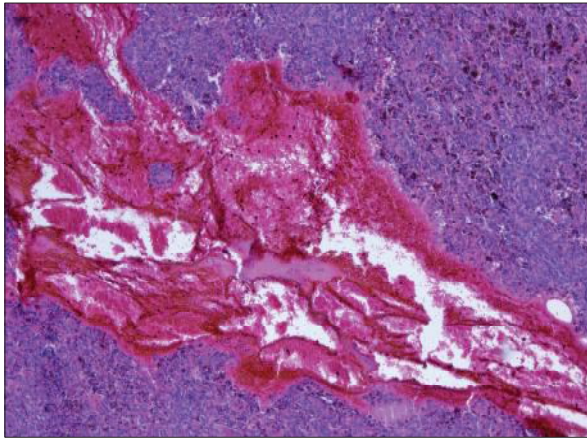


Figure 6. Histologic aspect of aneurysmal dermatofibroma. Hematoxylin-Eosin staining, x5.

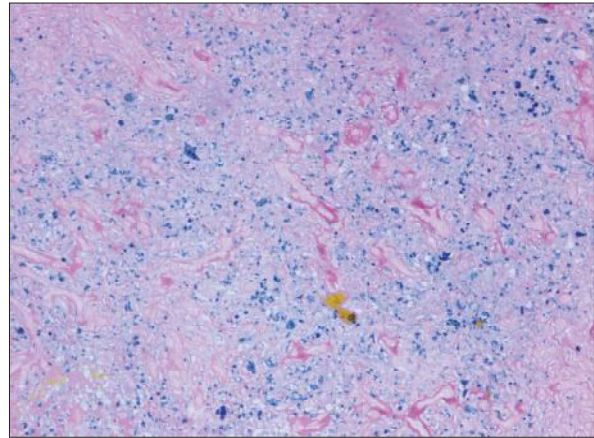


Figure 7. Hemosiderin deposits in Perls' Prussian Blue staining, x20.

## Discussions

When a classical dermatofibroma is identified, the diagnosis is usually straightforward, but non-common histologic subtypes exist - atypical, aneurysmal, cellular, clear cell, etc.

Aneurysmal fibrous histiocytoma variant is larger in size and has a higher rate of recurrence, up to 19%, compared with common dermatofibromas with a rate < 2% [10]. Also, aneurysmal DF's capacity of invasion in the subcutaneous tissue is noticeable, Alves *et al.* describing 81.8% invading aneurysmal histiocytomas in their study [11]. Moreover, in rare cases with cytogenetic aberration, the aneurysmal DF has the potential to metastasize in regional lymph nodes or lungs [9].

The exact etiology of DFs is unknown, but in an important percentage of reported cases, they were associated with a reactive process following previous local trauma or insect bites [3]. Recent cytogenetic analysis revealed genetic aberrations in aneurysmal histiocytoma and protein kinase C gene rearrangements [4,12]. Furthermore, disseminated lesions were described in immunosuppressive populations, secondary HIV infection, or immunosuppressive therapy [6]. These findings support the theory of the neoplastic origin of aneurysmal DF. The presented case reunites two possible etiological factors (insect bites and immunosuppression in

the context of chemotherapy for non-Hodgkin's lymphoma) and two different pathomechanisms (inflammatory and neoplastic).

The diagnosis of aneurysmal DF is established by histopathological evaluation. Histologically, it is characterized by hemorrhagic irregular cleft-like spaces mimicking vessels, but without endothelial lining. Aneurysmal DF should not be confused with malignant tumors, such as melanoma, nodular Kaposi sarcoma, angiosarcoma, or angiomatoid fibrous histiocytoma [13]. The latter is a subcutaneous neoplasm with systemic symptoms, containing monomorphic, desmin-positive cells. Cutaneous angiosarcoma is represented by vessels with atypical endothelial cells and numerous mitosis, while nodular Kaposi sarcoma progresses from patch and plaque to nodular phase and does not have fibrohistiocytic cells [14]. Finally, immunohistochemistry study helps in differentiating these malignant tumors from aneurysmal DF [15,16]. In the presented case, Perls's staining and the microscopic aspect of the lesion in hematoxylin-eosin were clear and immunohistochemistry was not necessary for the differential diagnosis.

The gold-standard treatment is surgical excision, but because of a high rate of recurrence, regular clinical follow-up of the patients with benign aneurysmal fibrous histiocytoma is necessary [17].

## Conclusions

The aneurysmal fibrous histiocytoma is a rare subtype of dermatofibroma, often confused by clinicians with malignant conditions because of its malignant-like macroscopic appearance. In the presented case, this particular dermatofibroma affects a woman with an insect bite, in the 7<sup>th</sup>

decade of life, diagnosed with non-Hodgkin lymphoma and immunosuppressive status. Given the high rate of recurrence and the possibility of multiple lesions in the context of immunosuppression, long-term reevaluation is mandatory.

*The article is an original work and the final form was not published before, printed or electronically.*

## Bibliography

1. Black J, Coffin CM, Dehner LP. Fibrohistiocytic tumors and related neoplasms in children and adolescents. *Pediatric and Developmental Pathology* 2012; p 181-210.
2. Berklite L, Ranganathan S, John I, et al. Fibrous histiocytoma/dermatofibroma in children: the same as adults? *Hum Pathol* 2020; p 107-115.
3. Zelger B, Zelger BG, Burgdorf WH. Dermatofibroma -a critical evaluation. *Int J Surg Pathol* 2004 Oct; p 333-44.
4. Plaszczyca A, Nilsson J, Magnusson L et al. Fusions involving protein kinase C and membrane associated proteins in benign fibrous histiocytoma. *Int J Biochem Cell Biol* 2014; p 475-81.
5. Jedrych JJ, Duraisamy S, Karunamurthy A. Aneurysmal fibrous histiocytomas with recurrent rearrangement of the PRKCD gene and LAMTOR1-PRKCD fusions. *J Cutan Pathol* 2018; p 966-968.
6. Queirós C, Uva L, Soares de Almeida L, et al. Multiple eruptive dermatofibromas associated with pregnancy - a case and literature review. *Dermatol Online J* 2019; 13030/qt29d3q6p1.
7. Juliandri J, Wang XY, Liu ZJ, et al. Dermoscopic patterns of dermatofibroma in 72 Chinese patients. *Chin Med J (Engl)* 2019; p 2121-2122.
8. Kondo RN, Ramires LA, Liberatti FB, et al. Giant aneurysmal dermatofibroma: a case of the rare variant of dermatofibroma. *J Dermat Cosmetol* 2019; p 159-161.
9. Doyle LA, Fletcher CD. Metastasizing "benign" cutaneous fibrous histiocytoma: a clinicopathologic analysis of 16 cases. *Am J Surg Pathol* 2013; p 484-95.
10. Burr DM, Peterson W, Peterson M. Aneurysmal Fibrous Histiocytoma: A Case Report and Review of the Literature. 2018.
11. Alves JCAVCADP, Matos DM, Barreiros HF, et al. Variants of dermatofibroma - a histopathological study. *An Bras Dermatol* 2014; p 472-7.
12. Walther C, Hofvander J, Nilsson J, et al. Gene fusion detection in formalin-fixed paraffin-embedded benign fibrous histiocytomas using fluorescence in situ hybridization and RNA sequencing. *Lab Invest* 2015; p 1071-1076.
13. Nabatanzi A, Male M, Qu XY, et al. Aneurysmal Fibrous Histiocytoma: Clinicopathology Analysis of 30 Cases of a Rare Variant of Cutaneous Fibrohistiocytoma. *Curr Med Sci* 2019; p 134-137.
14. Antony A, Kiran CM, Phansalkar M, et al. Aneurysmal Variant of Fibrous Histiocytoma - A Rare Entity Known for Recurrence. *Journal of Clinical and Diagnostic Research* 2017; p ED08-ED09.
15. Elder DE, Massi D, Scolyer RA, et al. Dermatofibroma (fibrous histiocytoma) and variants. *WHO (2018) Classification of Skin Tumors*. IARC Publications 2019; p 310-313.
16. Morariu SH, Suciú M, Vartolomei MD, et al. Aneurysmal dermatofibroma mimicking both clinical and dermoscopic malignant melanoma and Kaposi's sarcoma. *Rom J Morphol Embryol* 2014; p 221-224.
17. Cohen PR, Erickson CP, Calame A. Atrophic Dermatofibroma: A Comprehensive Literature Review. *Dermatol Ther (Heidelb)* 2019; p 449-468.

Conflict of interest  
NONE DECLARED

Correspondance address: Andreea-Raluca Szöke  
Mureş County Clinical Hospital, 540061 Târgu-Mureş, Romania.  
E-mail: szoke.andreea@yahoo.com