DEVELOPMENT OF PEMPHIGUS FOLIACEUS DURING PREGNANCY FOLLOWING COVID-19 VACCINATION - CASE REPORT

ANCA COJOCARU*, IOACHIM PREDA NAUMESCU**, LILIANA GABRIELA POPA*,**, GINA WAFI*, BEATRICE BĂLĂCEANU*, ALEXANDRA MARIA DOROBANȚU*, SIBEL ALI*, OLGUȚA ANCA ORZAN*,**

Summary

Pemphigus refers to a group of rare and severe autoimmune blistering diseases. Autoantibodies are directed against the cell surface of keratinocytes, resulting in a process called acantholysis.

Considering that pemphigus has a molecular mechanism and that there is an immune response alteration during the disease, several possible triggers have been discussed, including pregnancy. However, pemphigus is a disease that rarely occurs during pregnancy.

In response to the COVID-19 pandemic, various anti-COVID-19 vaccines have been developed. In the literature, there are extremely rare cases of flares or de novo development of autoimmune diseases, such as pemphigus vulgaris and bullous pemphigoid, within 2 weeks after COVID-19 vaccination.

We are presenting the case of a 34-year-old patient, from an urban area, who is admitted to the hospital for a well demarcated eruption consisting of crusted erosions placed on an erythematous base, with a seborrheic distribution, including the scalp, face and trunk, with no mucous membrane involvement. The lesions appeared two months ago, in the third trimester of pregnancy, 5 days after the second-dose of COVID-19 vaccine. The onset of the disease was subtle with a transient small flaccid blister located on her left breast, followed by the scalp and trunk involvement. In order to confirm the clinical diagnosis, a skin lesion biopsy was performed that certified the diagnosis of foliaceus pemphigus. Given the patient's postpartum status at the time of hospitalisation and the clinical appearance of the disease, it was decided to initiate systemic therapy with methylprednisolone, approximately 1 mg/kg/day that was slowly tapered.

Considering the relatively recent onset after vaccination and the low incidenceof pemphigus in pregnancy, we can hypothesise that the vaccine might actually be the trigger.

Keywords: *pemphigus foliaceus, autoimmune diseases, pregnancy, COVID-19 vaccine.*

Received: 23.05.2022 *Accepted: 20.06.2022*

Introduction

Pemphigus refers to a group of rare and severe autoimmune blistering diseases. The name is derived from the Greek pemphix, meaning blister or bubble. Autoantibodies are directed against the cell surface of keratinocytes, more precisely against two desmosomal adhesion proteins, desmoglein 1 and desmoglein 3, resulting in a process called acantholysis. Pemphigus can be divided into 2 major types: vulgaris and foliaceus. Patients with pemphigus vulgaris have mucosal erosions, cutaneous blisters and erosions. The blisters develop in the deeper part of the epidermis, just above the basal cell layer. Patients with pemphigus foliaceus only have cutaneous involvement. The blisters develop in the granular layer [1,2].

Considering that pemphigus has a molecular mechanism and that there is an immune response

* „Elias" Emergency University Hospital, Bucharest, Romania.
** University of Medicine and Pharmacy „Carol Davila", Bucharest, Romania.

alteration during the disease, several possible triggers have been discussed: drugs, infections, such as chronic hepatitis B and human immunodeficiency virus (HIV) infections, cancer, autoimmune conditions, radiotherapy, nutrients and micronutrients, stress, pregnancy. Pemphigus is a rare disease in pregnancy, pemphigus foliaceus being less common than pemphigus vulgaris [3].

In response to the COVID-19 pandemic, various anti-COVID-19 vaccines have been developed. Following injection, these vaccines have different common side effects, mostly not severe, such as: local redness, pain or swelling. After antiviral vaccinations, the clinical appearance of autoimmune diseases, including neurological, rheumatic and hematological diseases is rare. There have been extremely rare cases of flares of autoimmune bullous dermatoses such as pemphigus vulgaris and bullous pemphigoid [4].

Case Presentation

We are presenting the case of a 34-year-old patient, from an urban area, who was admitted to the hospital for a well demarcated eruption consisting of crusted erosions placed on an erythematous base, with a seborrheic distribution, including the scalp, face and trunk, with no mucous membrane involvement [Fig. 1A,B]. The Nikolsky sign was present. The lesions appeared two months ago, in the third trimester of pregnancy, 5 days after the second-dose of COVID-19 vaccine. The onset of the disease was subtle with a transient small flaccid blister located on her left breast, followed by the scalp and trunk involvement [Fig. 2].

The patient's medical history reveals no other significant pathology or family history.

The physical examination performed on admission found an overweight patient, other-

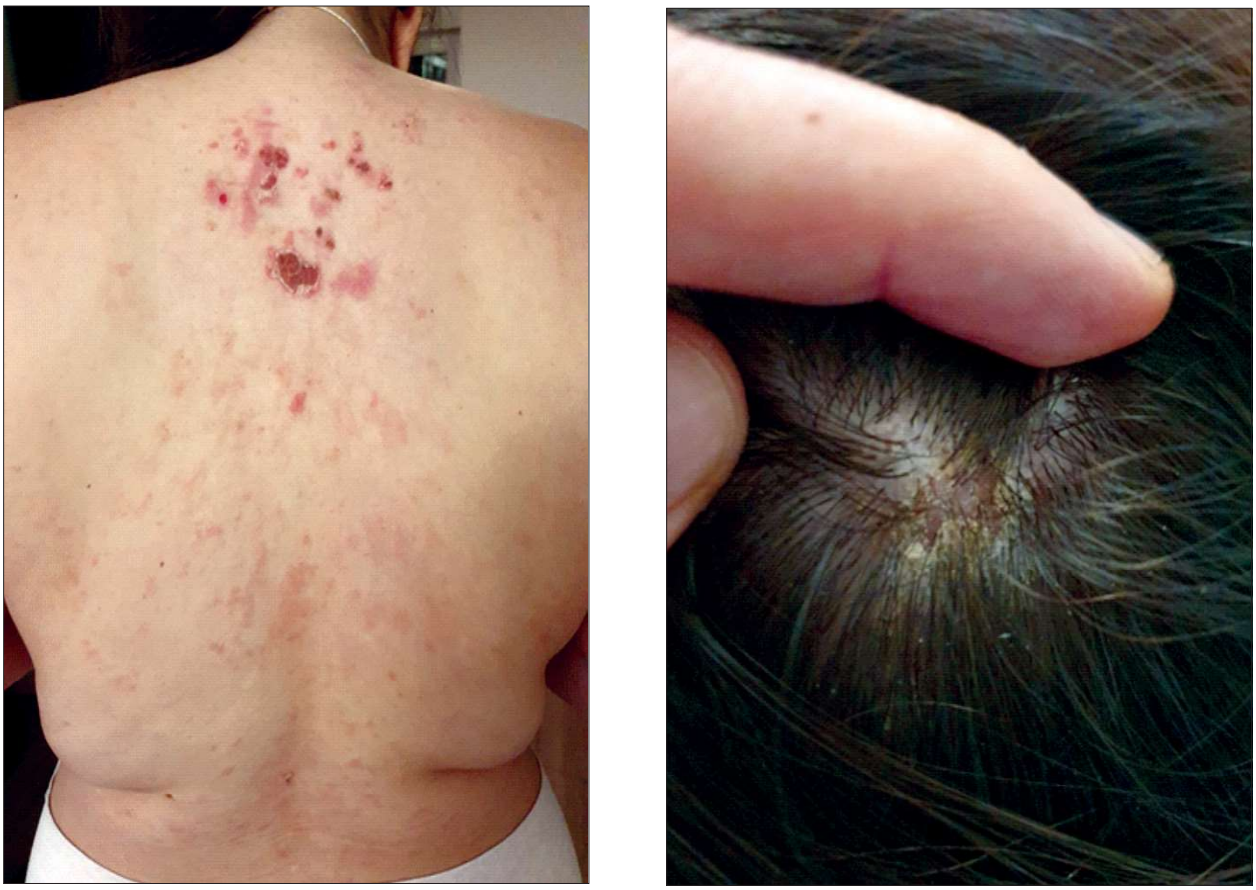

Figure 1. Crusted erosions placed on an erythematous base: (A) trunk, (B) scalp.

wise clinically normal. The laboratory tests were normal.

In order to confirm the clinical diagnosis, a skin lesion biopsy was done. The histopathology revealed detachment of the upper layers of the epidermis from the lower ones with the appearance of a suprabasal bulla, with neutrophils, with focal detachment of rounded keratinocytes from the upper layers (acantolysis). The perivascular and interstitial inflammatory infiltrate is composed of leukocytes and neutrophils [Fig. 3]. The histopathology diagnosed pemphigus and recommended direct immunofluorescence (DIF) test for immunoglobulin G (IgG) to clarify whether it is a pemphigus vulgaris or foliaceus.

Based on the clinical aspect with lesions located only on the skin (without the involvement of the mucous membranes) and relatively limited distribution, it was decided to delay the DIF test, pemphigus foliaceus being suggestive.

Given the patient's postpartum status at the time of hospitalisation and the clinical appearance of the disease, it was decided to initiate systemic therapy with methylprednisolone, approximately 1 mg/kg/day, followed by a slowly tapering of the dose. If the disease persists or spreads, intravenous immunoglobulin therapy may be considered.

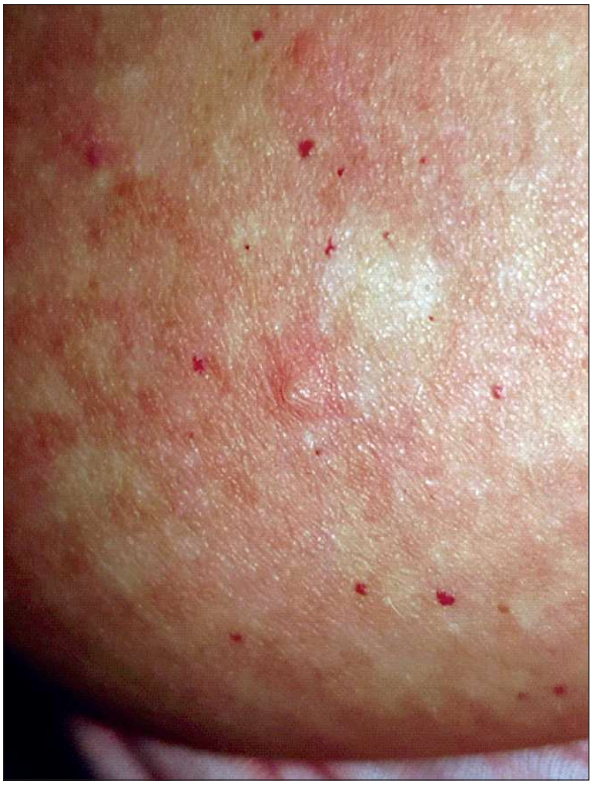

Figure 2. Transient small flaccid blister located on her left breast

Discussions

Pemphigus foliaceus is a rare acquired autoimmune blistering disease which appears equally in men and women and affects all races and ethnicities [5].

Despite the hormonal and immunological changes during conception and pregnancy, pemphigus foliaceus may occur or aggravate in pregnancy. Kokolios et al. reported a case of a 36-year-old female patient, with no history of skin lesions,who was admitted to the hospital with pemphigus foliaceus onset during pregnancy [6]. A study conducted during 1966-2014, revealed a number of 47 cases of pemphigus, diagnosed before or after pregnancy, of which only two cases of new onset pemphigus foliaceus during pregnancy [7]. Daneshpazhooh et al. found only one case of pemphigus foliaceus during pregnancy by reviewing the files of patients diagnosed with pemphigus between 1984 and 2006 [8].

Regarding the potential link between COVID-19 vaccination and the onset of pemphigus, Solimani et al. described the first case of pemphigus vulgaris which occurred 5 days after the first-dose of vaccine and worsened after the second-dose [9]. Another study described five cases of bullous pemphigoid and

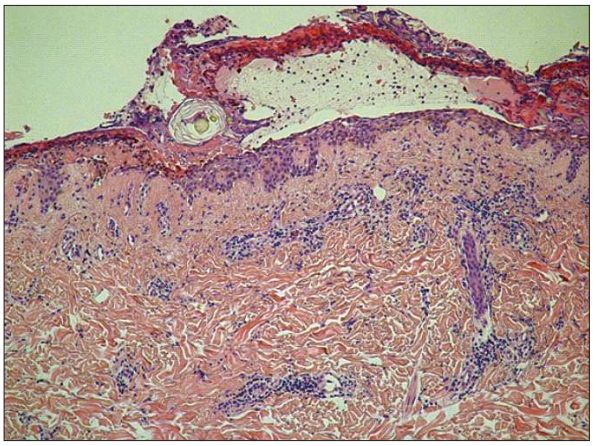

Figure 3. Histopathological examination.

pemphigus vulgaris with a flare up of the disease 2 weeks after the first-dose of COVID-19 vaccine [10]. Knechtl et al. reported a case of pemphigus vulgaris in an 89-year-old patient, which developed one month after COVID-19 vaccination [11].

Conclusions

In conclusion, we report a case where pemphigus foliaceus developed during pregnancy, following COVID-19 vaccination.

Considering the relatively recent onset after vaccination and the low incidence of pemphigus in pregnancy, we can hypothesise that the vaccine might actually be the trigger.

Bibliography

1. Schmidt E, Kasperkiewicz M, Joly P. Pemphigus. Lancet. 2019 Sep 7;394(10201):882-894. doi: 10.1016/S0140-6736(19)31778-7. PMID: 31498102.
2. Melchionda V, Harman KE. Pemphigus vulgaris and pemphigus foliaceus: an overview of the clinical presentation, investigations and management. Clin Exp Dermatol. 2019 Oct;44(7):740-746. doi: 10.1111/ced.14041. Epub 2019 Aug 4. PMID: 31378971.
3. Tavakolpour S. Pemphigus trigger factors: special focus on pemphigus vulgaris and pemphigus foliaceus. Arch Dermatol Res. 2018 Mar;310(2):95-106. doi: 10.1007/s00403-017-1790-8. Epub 2017 Nov 6. PMID: 29110080.
4. McMahon DE, Amerson E, Rosenbach M, Lipoff JB, Moustafa D, Tyagi A, Desai SR, French LE, Lim HW, Thiers BH, Hruza GJ, Blumenthal KG, Fox LP, Freeman EE. Cutaneous reactions reported after Moderna and Pfizer COVID-19 vaccination: A registry-based study of 414 cases. J Am Acad Dermatol. 2021 Jul;85(1):46-55. doi: 10.1016/j.jaad.2021.03.092. Epub 2021 Apr 7. PMID: 33838206; PMCID: PMC8024548.
5. James KA, Culton DA, Diaz LA. Diagnosis and clinical features of pemphigus foliaceus. Dermatol Clin. 2011 Jul;29(3):405-12, viii. doi: 10.1016/j.det.2011.03.012. PMID: 21605805; PMCID: PMC3108573.
6. Kokolios M, Lamprou F, Stylianidou D, Sotiriadis D, Patsatsi A. New onset pemphigus foliaceus during pregnancy: A rare case. Int J Womens Dermatol. 2017 Dec 8;4(2):109-112. doi: 10.1016/j.ijwd.2017.10.010. PMID: 29872686; PMCID: PMC5986257.
7. Lin L, Zeng X, Chen Q. Pemphigus and pregnancy. Analysis and summary of case reports over 49 years. Saudi Med J. 2015 Sep;36(9):1033-8. doi: 10.15537/smj.2015.9.12270. PMID: 26318458; PMCID: PMC4613625.
8. Daneshpazhooh M, Chams-Davatchi C, Valikhani M, Aghabagheri A, Mortazavizadeh SM, Barzegari M, Akhyani M, Hallaji Z, Esmaili N, Ghodsi SZ. Pemphigus and pregnancy: a 23-year experience. Indian J Dermatol Venereol Leprol. 2011 Jul-Aug;77(4):534. doi: 10.4103/0378-6323.82404. PMID: 21727712.
9. Solimani F, Mansour Y, Didona D, Dilling A, Ghoreschi K, Meier K. Development of severe pemphigus vulgaris following SARS-CoV-2 vaccination with BNT162b2. J Eur Acad Dermatol Venereol. 2021 Oct;35(10):e649-e651. doi: 10.1111/jdv.17480. Epub 2021 Jul 12. PMID: 34169588; PMCID: PMC8447452.
10. Damiani G, Pacifico A, Pelloni F, Iorizzo M. The first dose of COVID-19 vaccine may trigger pemphigus and bullous pemphigoid flares: is the second dose therefore contraindicated? J Eur Acad Dermatol Venereol. 2021 Oct;35(10):e645-e647. doi: 10.1111/jdv.17472. Epub 2021 Jul 13. PMID: 34169578; PMCID: PMC8447358.
11. Knechtl GV, Seyed Jafari SM, Berger T, Rammlmair A, Feldmeyer L, Borradori L. Development of pemphigus vulgaris following mRNA SARS-CoV-19 BNT162b2 vaccination in an 89-year-old patient. J Eur Acad Dermatol Venereol. 2022 Apr;36(4):e251-e253. doi: 10.1111/jdv.17868. Epub 2021 Dec 22. PMID: 34897817.

Conflict of interest

NONE DECLARED

Correspondance address: Olguța Anca Orzan
„Elias" Emergency University Hospital,
Department of Dermatology and Allergology, 17 Mărăști Blvd, Bucharest, Romania,
e-mail: olguta@gmail.com