CLINICAL CASES

INFLAMMATORY BOWEL DISEASE IN THE CONTEXT OF BIOLOGIC THERAPY FOR PSORIASIS: A CASE PRESENTATION

ANA ION*,**, CRISTIAN GEORGE ȚIERANU*,***, ALEXANDRA MARIA DOROBANȚU**, CĂLIN GIURCĂNEANU*,**, OLGUȚA ANCA ORZAN*,**

Summary

Psoriasis is a chronic, inflammatory, multisystemic disease whose onset is triggered by genetic and environmental factors. Psoriasis has been associated with a wide range of comorbid conditions, namely metabolic syndrome, psoriatic arthritis, cardiovascular disease, psychiatric disorders, malignancy, as well as inflammatory bowel disease. Nowadays, patients affected by chronic plaque psoriasis may benefit from safe and efficient novel therapeutic options. Nevertheless, for patients affected by both psoriasis and inflammatory bowel disease, there is a strong recommendation to avoid biologic therapy with interleukin 17 inhibitors since they may trigger an exacerbation of the gastrointestinal symptoms. Moreover, inflammatory bowel disease in psoriasis patients under biologic therapy with interleukin 17 inhibitors has been reported. In this paper we present the case of a 33-year-old Male patient with a long-standing history of chronic plaque psoriasis under interleukin 17 inhibitors, previously treated with metho-trexate. Throughout the period under immunosuppressive therapy with methotrexate, the patient mentioned mild gastrointestinal symptoms, who persisted after switching to biologic therapy. The patient correlated these symptoms with poor dietary habits. Nevertheless, the patient was referred to the Gastroenterology Department for further investigations. The correlation between the levels of the fecal calprotectin, the endoscopic and histopathologic examination of the biopsies from the terminal ileum led to the diagnosis of Crohn's-like ileitis possibly in the context of biologic therapy with an interleukin 17 inhibitor. The therapeutic approach consisted in cessation of biologic therapy with secukinumab and corticosteroid therapy, with proper control of the inflammatory bowel disease. The management of chronic plaque psoriasis consisted in initiating the patient on risankizumab, an interleukin 23 inhibitor.

***Key words**: IL-17 inhibitors adverse effects, biologic therapy psoriasis, secukinumab adverse reactions.*

Acceptat: 17.02.2023 *Accepted: 13.03.2023*

* 'Carol Davila' University of Medicine and Pharmacy, Bucharest, Romania.
** Department of Dermatology, 'Elias' Emergency University Hospital, Bucharest, Romania.
*** Department of Gastroenterology "Elias" Emergency University Hospital, Bucharest.

Introduction

Psoriasis is an inflammatory, multisystemic disease with a chronic course which affects approximately 2-3% of the population globally [1]. The onset of the psoriatic disease is mainly determined by the remarkable interplay between genetic and environmental factors which further predispose to the psoriasis phenotype [2]. The pathophisyology of psoriasis is complex and consists in the activation of both keratinocytes and dendritic cells which produce an increased amount of proinflammatory cytokines, namely tumor necrosis factor alpha (TNF-alpha), interleukin-1 βeta (IL-1β), interleukin-17 (IL-17), interleukin-22 (IL-22), interleukin-23 (IL-23) [2]. These cytokines activate T cells which migrate toward the cutaneous site of inflammation where they secrete effector molecules that further stimulate keratinocytes which results in a cascade of cytokines and chemokines that continue to activate inflammatory cells, the consequence being a locally permanent proinflammatory state [2-4].

The comprehensive understanding of the pathophysiology of psoriasis led to outstanding advances in the development of efficient and safe novel therapeutic options. [5]. However, in many instances, the comorbid conditions associated with psoriasis may impact the decision of selecting one therapeutic class over another [5]. For patients affected by both psoriasis and inflammatory bowel disease (IBD), first line therapy is represented by TNF-alpha inhibitors, with a second line therapy involving ustekinumab and IL-23 inhibitors, a strong recommendation being to avoid IL-17 inhibitors [5]. In the last years it has been found that IL-17 inhibitors may be associated with the onset or exacerbation of IBD [6-8].

Case presentation

We present the case of a 33-year-old male patient with the diagnosis of moderate-severe psoriasis undergoing biologic therapy with secukinumab who developed Crohn's-like ileitis after ten months of treatment.

The patient had a personal history of moderate-severe psoriasis which has been diagnosed in August 2014 and has been treated with methotrexate, 15 mg per week for seven years, until 2021, when the medication not only became ineffective, but also led to liver enzymes elevation. Throughout the period under immuno-suppressive therapy with methotrexate, the patient reported unspecified, mild, gastrointestinal symptoms consisting in an accelerated intestinal transit. No personal or family history of inflammatory bowel disease was established, therefore, in November 2021, the patient was initiated on biologic therapy with an IL-17 inhibitor, namely secukinumab. A significant improvement in both Dermatology Life Quality Index (14 before biologic therapy compared with 0 at the 12-week evaluation) and Psoariasis Area Severity Index (29.6 before biologic therapy compared with 0 at the 12-week evaluation) was noticed at the 12-week evaluation, therefore suggesting an optimal control of psoriasis. Nevertheless, at the the six-month evaluation from October 2022, the patient mentioned that he still presented those mild gastrointestinal symptoms, but he correlated them with poor dietary habits. A collaborative approach between the Dermatology and Gastroenterology Departments was conducted for further investigations. Fecal calprotectin was tested and, initially, it had slightly increased values. Microbiological investigations on stool sample were made and infections were ruled out. At the following evaluation, because a significant increase in the calprotectin levels was found, as seen in figure 1, a colonoscopy with endoscopic biopsies was performed. The endoscopic examination revealed multiple ulcerations accompanied by a pronounced erythema and edema of the mucosa in the terminal ileum (figure 2, figure 3). Multiple biopsies were taken from the terminal ileum. The histopathologic examination showed acute inflammatory changes, suggesting a recent onset and a self-resolving course of the disease (figure 4, figure 5).

From the correlation between the patient's personal history of psoriasis under biologic therapy and the results from the laboratory, endoscopic and histopathologic examinations, the established diagnosis was Crohn's like ileitis in the context of biologic therapy with an IL-17 inhibitor. The therapeutic approach consisted in corticosteroid therapy with budesonide, tapered

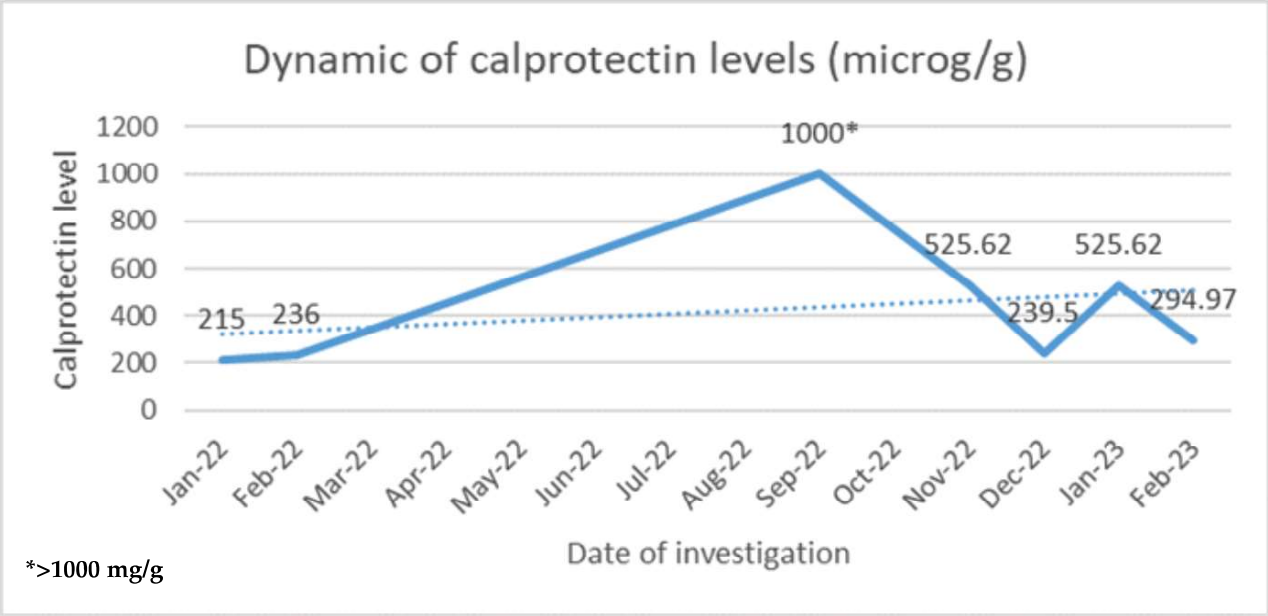

Figure 1. Dynamic of calprotectin levels between January 2022 and February 2023.

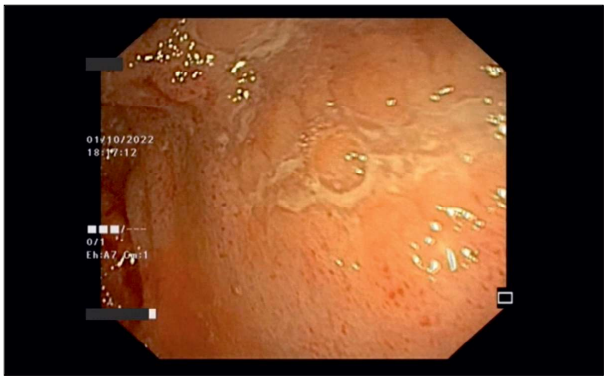

Figure 2. Ileal mucosa with linear ulceration and surrounding erythema.

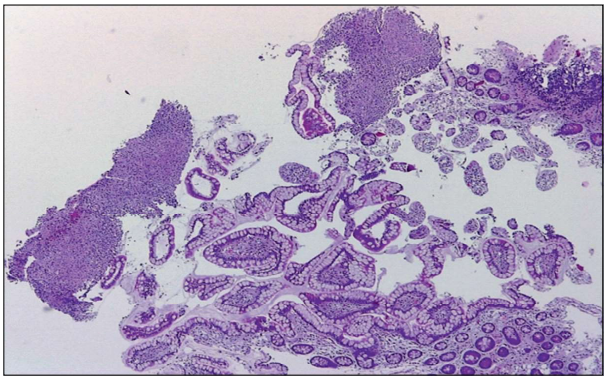

Figure 4. Ileal mucosa. HE 100x. Acute inflammatory changes necrotic debris.

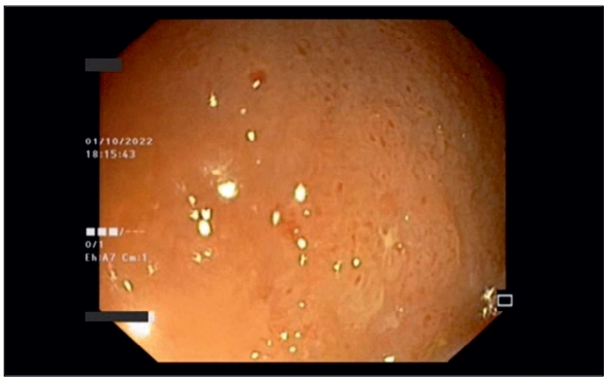

Figure 3. Ileal mucosa: Aphthous ulceration and acute edematous changes of the mucosa.

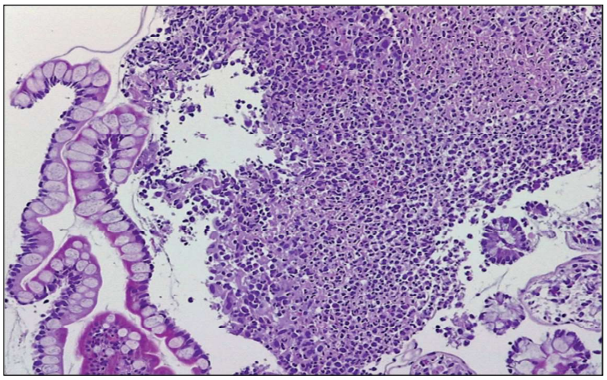

Figure 5. Ileal mucosa – detail. HE 400x. Necrotic debris, fibrin and inflammatory infiltrate consisting mainly in neutrophils.

over a three-month period. A proper control of the IBD with clinical remission was obtained.

Since it was established that the gastro-intestinal symptoms may have appeared due to the use of biologic therapy with secukinumab for psoriasis, a multidisciplinary decision between the dermatologist and the gastroenterologist was performed. Therefore, the patient was switched to Risankizumab. This IL-23 inhibitor has proven to be efficacious in maintaining clinical remission of IBD, while being a proper therapeutic option for psoriasis, as well. The patient continued follow-up at the Dermatology Department, as well as the Gastroenterology Department.

Discussions

Psoriasis and IBDs are inflammatory diseases with a chronic course marked by relapses and periods of clinical inactivity [9]. Epidemiological studies have been able to establish that there is, indeed, a strong bidirectional association between psoriasis and IBD [9, 10]. We found that other similar cases have been reported in the scientific literature in the last years [11-19]. Our case presentation aims at increasing awareness on the importance of carefully monitoring patients affected by psoriasis under biologic therapy for additional symptoms, as well as on the necessity of a multidisciplinary approach.

Bibliography

1. Boehncke WH, Schön MP. Psoriasis. Lancet. 2015;386(9997):983-94.
2. Mahil SK, Capon F, Barker JN. Update on psoriasis immunopathogenesis and targeted immunotherapy. Semin Immunopathol. 2016;38(1):11-27.
3. Chung Y, Chang SH, Martinez GJ, Yang XO, Nurieva R, Kang HS, Ma L, Watowich SS, Jetten AM, Tian Q, et al. Critical regulation of early Th17 cell differentiation by interleukin-1 signaling. Immunity. 2009;30(4):576-87.
4. Zaba LC, Cardinale I, Gilleaudeau P, Sullivan-Whalen M, Suárez-Fariñas M, Fuentes-Duculan J, Novitskaya I, Khatcherian A, Bluth MJ, Lowes MA, et al. Amelioration of epidermal hyperplasia by TNF inhibition is associated with reduced Th17 responses. J Exp Med. 2007;204(13):3183-94.
5. Jiang Y, Chen Y, Yu Q, Shi Y. Biologic and Small-Molecule Therapies for Moderate-to-Severe Psoriasis: Focus on Psoriasis Comorbidities. BioDrugs. 2023;37(1):35-55.
6. Gordon KB, Blauvelt A, Papp KA, Langley RG, Luger T, Ohtsuki M, Reich K, Amato D, Ball SG, Braun DK, et al. Phase 3 Trials of Ixekizumab in Moderate-to-Severe Plaque Psoriasis. N Engl J Med. 2016;375(4):345-56.
7. Reich K, Leonardi C, Langley RG, Warren RB, Bachelez H, Romiti R, Ohtsuki M, Xu W, Acharya N, Solotkin K, et al. Inflammatory bowel disease among patients with psoriasis treated with ixekizumab: A presentation of adjudicated data from an integrated database of 7 randomized controlled and uncontrolled trials. J Am Acad Dermatol. 2017;76(3):441-8.e2.
8. Schreiber S, Colombel JF, Feagan BG, Reich K, Deodhar AA, McInnes IB, Porter B, Das Gupta A, Pricop L, Fox T. Incidence rates of inflammatory bowel disease in patients with psoriasis, psoriatic arthritis and ankylosing spondylitis treated with secukinumab: a retrospective analysis of pooled data from 21 clinical trials. Ann Rheum Dis. 2019;78(4):473-9.
9. Fu Y, Lee CH, Chi CC. Association of Psoriasis With Inflammatory Bowel Disease: A Systematic Review and Meta-analysis. JAMA Dermatol. 2018;154(12):1417-23.
10. Alinaghi F, Tekin HG, Burisch J, Wu JJ, Thyssen JP, Egeberg A. Global Prevalence and Bidirectional Association Between Psoriasis and Inflammatory Bowel Disease-A Systematic Review and Meta-analysis. J Crohns Colitis. 2020;14(3):351-60.
11. Wang J, Bhatia A, Krugliak Cleveland N, Gupta N, Dalal S, Rubin DT, Sakuraba A. Rapid Onset of Inflammatory Bowel Disease after Receiving Secukinumab Infusion. ACG Case Rep J. 2018;5:e56.
12. Philipose J, Ahmed M, Idiculla PS, Mulrooney SM, Gumaste VV. Severe de novo Ulcerative Colitis following Ixekizumab Therapy. Case Rep Gastroenterol. 2018;12(3):617-21.
13. Haidari W, Al-Naqshabandi S, Ahn CS, Bloomfeld RS, Feldman SR. Asymptomatic Crohn's disease identified in a patient being treated with secukinumab: A case report. SAGE Open Med Case Rep. 2019;7:2050313x19893580.

14. Smith MK, Pai J, Panaccione R, Beck P, Ferraz JG, Jijon H. Crohn's-like disease in a patient exposed to anti-Interleukin-17 blockade (Ixekizumab) for the treatment of chronic plaque psoriasis: a case report. BMC Gastroenterol. 2019;19(1):162.
15. Achufusi TG, Harnee PS, Rawlins S. A Rare Case of New-Onset Ulcerative Colitis following Initiation of Secukinumab. Case Rep Med. 2019;2019:2975631.
16. Merino Gallego E, Gómez Torres K, Martínez Amate E. Debut Of Inflammatory Bowel Disease Associated To Ixekizumab In Patient With Moderate, Difficult -To-Manage Psoriasis. Gastroenterol Hepatol. 2020;43(10):622-3.
17. Nazarian A, Grin A, Wijeratne DT. Ixekizumab Associated New-Onset Inflammatory Bowel Disease. ACG Case Rep J. 2020;7(2):e00316.
18. Marin M, Alzueta N, Pío M, Gascón A, Castresana M. Ulcerative colitis induced by ixekizumab: a case report. Eur J Hosp Pharm. 2021;28(1):50-2.
19. Mu X, Fardy J, Reid S, Trahey J. Severe drug-associated colitis with Crohn's features in setting of ixekizumab therapy for chronic plaque psoriasis. BMC Gastroenterol. 2021;21(1):361.

Conflict of interest
NONE DECLARED

Correspondance address: Alexandra Maria Dorobanțu
Department of Dermatology, „Elias" Emergency University Hospital, Bucharest, Romania;
E-mail: alexandramdorobantu@gmail.com