PEMPHIGOID GESTATIONIS ASSOCIATED WITH NEONATAL PEMPHIGUS: CASE PRESENTATION

MĂDĂLINA AURELIA HUSARIU*, ROXANA IOANA ILCUȘ*, ȘERBAN-PESCAR DIANA**, OANA MIRELA TIUCĂ ***, OVIDIU S. COTOI, ****, SILVIU-HORIAMORARIU***

Summary

Pemphigoid gestationis is a rare pregnancy-specific bullous condition associated with fetal risk. Diagnosis and treatment are challenging because of the difficulties in identifying and addressing the disease and the risks associated with treatment, which often involve an individualized therapeutic approach. We present a clinical case of pemphigoid gestationis with neonatal transmission, illustrating essential aspects of diagnosis and management in a clinical context, highlighting aspects of differential diagnosis and challenges in the management of this condition.

Key words: *pemphigoid gestationis, neonatal pemphigus, pregnancy.*

Received: 03.06.2024 *Accepted: 29.06.2024*

Introduction

Pemphigoid gestationis (PG) is a rare bullous condition associated with pregnancy with late onset in the second or third trimester of pregnancy or immediately postpartum, which, although often self-limiting, can be recurrent, so it tends to affect subsequent pregnancies as well. In the case of recurrences, the onset is faster and presents higher severity [1]. PG is associated with foetal risk, causing intrauterine growth restriction, preterm birth or low birth weight [2].

The incidence varies from 1:20,000 to 1:50,000 pregnancies. Very rarely, the association is described outside of the pregnancy period in women with trophoblastic tumours, as a paraneoplastic phenomenon[3,4]. In 3% to 10% of cases, autoantibodies cross the placenta and induce neonatal pemphigus [5].

Given the low frequency of occurrence, variations in clinical presentation, and therapeutic difficulties, the diagnosis and management of this condition can be a clinical challenge.

Case presentation

A 23-year-old pregnant patient at 20-21 weeks of gestation (GW), with three previous pregnancies and child births (tripara), addressed the Dermatology service with the sudden onset of a skin rash consisting of well-defined erythematous plaques and patches, on the surface of which there were tense bullae, with serous citrine

* Dermatovenereology Clinic, Mureș County Clinical Hospital, Târgu-Mureș, Romania
** Dermatovenereology Department, "Dr. Eugen Nicoară" Municipal Hospital, Reghin, Romania
*** Dermatology Discipline, "George Emil Palade" University of Medicine and Pharmacy, Sciences and Technology, Târgu-Mureș, Romania
**** Physiopathology Discipline, "George Emil Palade" University of Medicine and Pharmacy, Sciences and Technology, Târgu-Mureș, Romania

content and post-bullous erosions, located on both thighs, arms and forearms, palms and soles and on the distended abdomen, without the involvement of mucous membranes (fig.1), associating continuous intense itching. On dermatoscopic examination, an intact translucent bulla is identified, located on an erythematous base, translucent yellow areas, fine white scales and serous crusts (fig. 2). From the personal pathological antecedents, it appears that the patient presented a similar skin rash during the previous pregnancy, but smaller and self-limited. Laboratory tests revealed an inflammatory syndrome with values of C-reactive protein (CRP) = 6.86 mg/dl and ESR = 35 mm/h.

A skin biopsy was performed with a histopathological examination that described a vesiculo-bullous lesion with a sub-basal cleavage plane, which caused the detachment of the epithelium immediately at the level of the dermo-epidermal junction. A mixed inflammatory infiltrate composed of eosinophils, lymphocytes, histiocytes and numerous red blood cells is observed at the level of the cleavage plane. Eosinophils are predominantly located under the

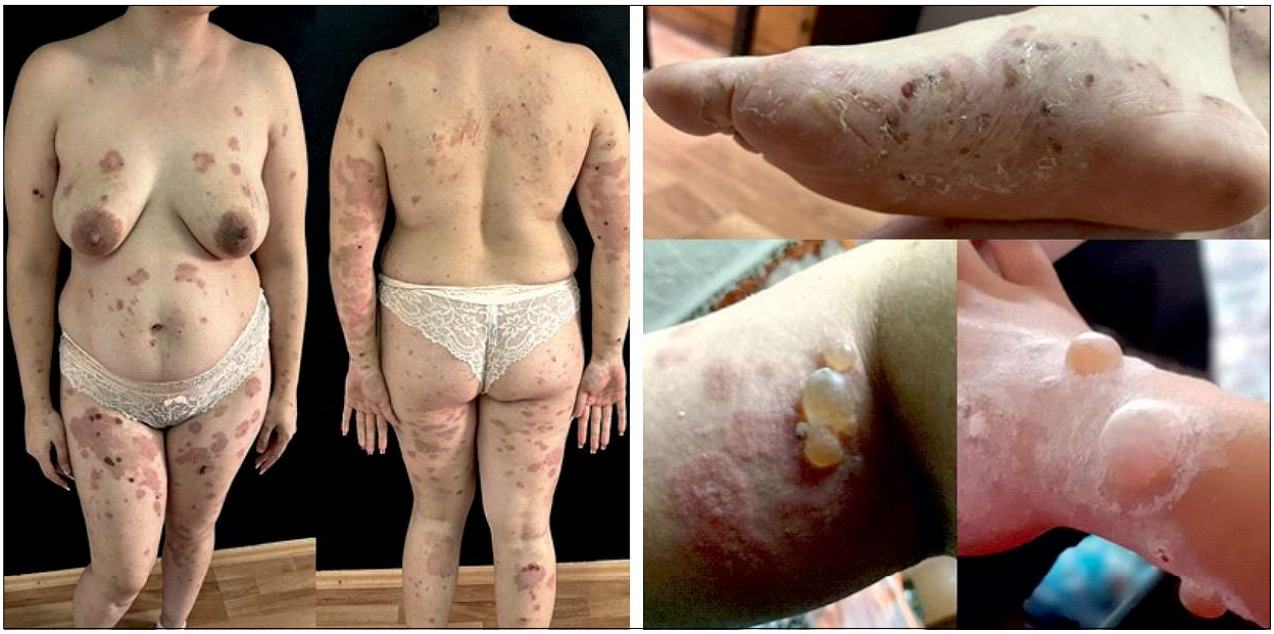

Figure 1. Clinical appearance – Pemphigoid gestationis

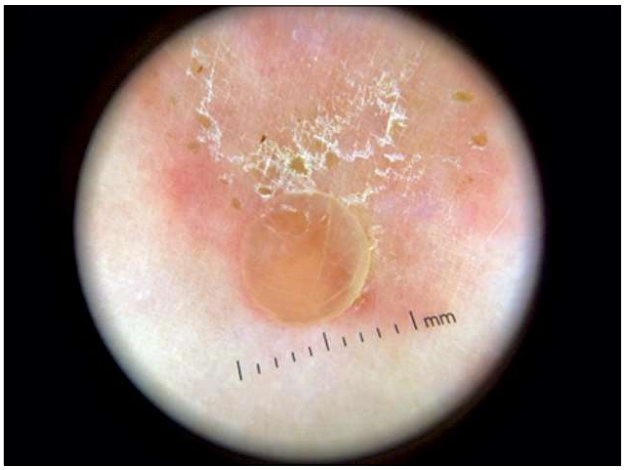

Figure 2. Dermatoscopic appearance

cleavage area, but also in the perivascular dermis (Fig. 3). Direct immunofluorescence and determination of anti-BP 180 antibodies could not be performed for technical and financial reasons.

Based on the anamnesis and the clinical and histopathological examination criteria, the diagnosis of pemphigoid gestationis was established.

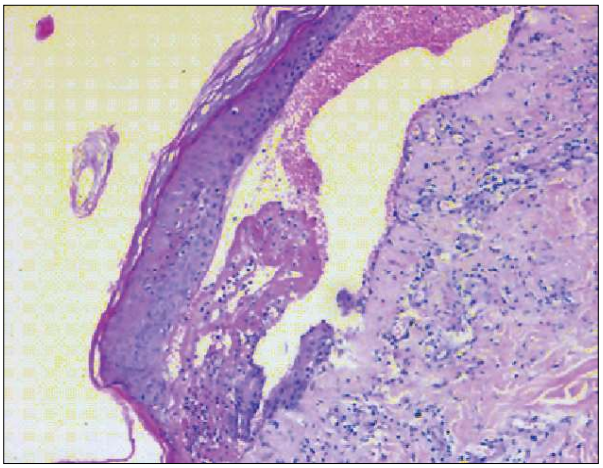

Figure 3. Histopathological appearance (Col. HE, ob. 10x)

Systemic treatment with corticosteroids was initiated - Prednisone 5 mg by titration for the lowest effective dose: 25 mg/day alternatively with 20 mg/day and antihistamine - Loratadine 10 mg/day, along with local treatment with dermatocorticoids - Hydrocortisone butyrate. When trying to reduce the dose of Prednisone below 25 mg, the patient presented the appearance of new erythematous-bullous lesions, which is why she continued systemic corticosteroid therapy throughout the pregnancy, under the careful monitoring of the dermatologist and the gynaecologist.

The patient gave birth prematurely to a live, female newborn with a birth weight (BW) of 2840 g, who presented with a skin rash consisting of erythematous papules and vesicles disseminated throughout the body (Fig. 4). At the check-up performed one month postpartum, remission of the skin rash was found in both the mother and the newborn.

Discussions

During pregnancy, >90% of pregnant women have skin damage, given the hormonal and metabolic changes [6]. In a theoretical context, a

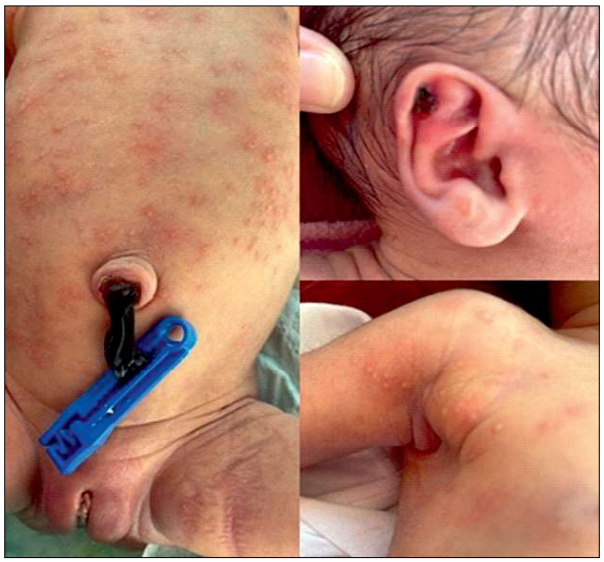

Figure 4. Clinical appearance: disseminated erythema, papules and vesicles supporting the diagnosis of neonatal pemphigus.

dermatosis is classified as pregnancy-specific when it first begins during pregnancy or immediately postpartum and is considered to be the direct result of the influence of the gestational state, after all other conditions that could overlap the pregnancy period have been excluded [2].

Pemphigoid gestationis was formerly known as herpes gestationis, until Holmes and Black proposed in 1982 a change in the nomenclature, to reflect the clinical and immunopathological relationship between PG and the group of bullous conditions, while emphasizing the absence of any evidence of genuine herpetic infection [7].

Although the aetiology remains uncertain, a complex pathogenic mechanism composed of immunogenetic and hormonal factors has been suggested as triggering the disease. At present, the main trigger is thought to be an abnormality in the expression of major histocompatibility complex class II (MCH) molecules in the placenta, which causes a maternal allogeneic response. The main allogeneic determinant is collagen type XVII, also known as BP180, a transmembrane hemidesmosome glycoprotein of ectodermal origin, present in both the skin and the placenta. Triggering of the aberrant immune response produces IgG1-type antibodies that cross-react with collagen XVII in the skin,

forming immune complexes and thus inducing tissue damage [3, 7, 8].

From a clinical point of view, pemphigoid gestationis is initially manifested by the appearance of a rash consisting of intensely pruritic urticarial papules, which tend to coalesce into plaques, at which point it is very difficult to distinguish it from a polymorphous rash of pregnancy. The diagnosis begins to take shape a few days/weeks later, when a generalized pemphigoid-like eruption consisting of tense bullae with serous content appears. A useful aspect in establishing the clinical diagnosis is represented by the distribution of the rash, which in the case of pemphigoid gestationis, tends to be located at the periumbilical level, with subsequent extension to the entire distended abdomen and thighs, with possible generalization, including to the palmoplantar area, but without the involvement of the face and mucous membranes, an aspect also found in the presented clinical case [2, 6, 8].

Although the clinical criteria are decisive for establishing the diagnosis, a series of paraclinical investigations can be carried out to consolidate the positive diagnosis. In this sense, skin biopsy is a useful tool. The histopathological examination in the case of PG reveals a bullous lesion with a sub-basal cleavage plane, without acantholysis, with a subepidermal inflammatory infiltrate, an aspect also described in the case of the presented patient. In addition, direct immunofluorescence reveals linear deposition along the basement membrane of complement C3, which can remain positive from 6 months to 4 years after clinical resolution of signs [7]. Also, the identification by ELISA methods of anti-BP180 antibodies can be carried out, their level being correlated with the activity of the disease [8].

Therapeutic options vary according to the stage and severity of the disease, and an important aspect is represented by the limitations induced by the safety profile of the drugs in pregnant women. In the treatment of pemphigoid gestationis, in cases with localized lesions, topical corticosteroids of low or moderate potency are used, to which an oral antihistamine can be associated to control pruritus [9]. Antihistamines included in safety category B are recommended for pregnant women, such as: Chlorpheniramine, Loratadine or Levocetirizine [6]. In the bullous phase or in cases where >10% of the body surface is affected, systemic administration of corticosteroids is recommended. In this sense, a dose of 0.5 mg/kg BW of Prednisolone is recommended, with the possibility of increasing the dose up to 2 mg/kg BW for a short period. Other treatment options cited in the literature are Ciclosporin, Azathioprine, i.v. Immunoglobulins or Rituximab, but there are limited studies on their safety [7].

Foetal risk has been shown to be associated with disease severity rather than corticosteroid treatment as previously thought [10,11]. In 3% to 10% of PG cases, IgG autoantibodies cross the placenta and induce neonatal pemphigus [3]. A study conducted in Japan showed that the level of circulating antibodies in the foetus is comparable to that of the mother[12]. However, follow-up guidelines for pregnancies complicated by PG have not been published, and there are no data on the long-term prognosis of children from mothers with PG, most likely due to the rarity of the condition [13].

The particularity of the presented clinical case resides in the recurrent nature of the condition, evidenced by the appearance of the rash during a previous pregnancy. This aspect supports the recurrent character frequently described in the literature and requires the prophylaxis of possible subsequent pregnancies, given the escalation of the severity of the rash with each pregnancy and the possible associated fetal risks (intrauterine growth restriction, premature birth, low birth weight). The lack of self-limiting character supported by the persistence of the rash throughout pregnancy and in the immediate postpartum period represents a particularity with implications in pregnancy management. The presence of skin lesions characteristic of neonatal pemphigus in the newborn is a rare association, this correlation underlining the clinical importance and the need for careful monitoring of the newborn in the perinatal period.

Conclusions

Pemphigoid gestationis is a complex condition with varied implications during pregnancy. The early diagnosis of this condition is the first key to ensure the most effective maternal and foetal management, given the specific clinical manifestations and the potential to influence the normal course of pregnancy. The risks and benefits of treatment should be thoroughly discussed with the patient. Women with a history of pemphigoid gestationis should be counselled regarding the risk of recurrence in subsequent pregnancies. Medium/long-term monitoring of both mothers and children born following pregnancies complicated by pemphigoid gestationis is required. This approach brings to the fore not only the diagnostic and therapeutic challenges of this complex condition, but also the importance of careful management to ensure the health of both mother and newborn. By understanding and approaching the disease correctly, we can contribute to improving the quality of life of pregnant women and preventing risks associated with the health of the foetus during the perinatal period. A multidisciplinary approach involving a dermatologist, obstetrician, pathologist and neonatologist is essential to provide optimal care to pregnant women and prevent risks to the health of the foetus.

Ethics: The patient's rights were respected in accordance with the Declaration of Helsinki. The patient has expressed her agreement to the reporting of the case, in compliance with the GDPR regulations in force. The presented case has not been published and has not been submitted for publication in another journal.

Bibliography

1. Mark A. B. Et al., Dermatoses of pregnancy, Clinical obstetrics and gynecology, Volume 58, Number 1, 104–111, 2015.
2. Maria Magdalena Roth, Pregnancy Dermatoses, Am J Clin Dermatol 2011; 12 (1): 25-41.
3. Caliopia Gavril Parfeneet al., Influence of pemphigoid gestationis on pregnancy outcome: A case report and review of the literature, Experimental and therapeutic medicine 23: 23, 2022.
4. Giovanni Genovese et al., A Systematic Review of Treatment Options and Clinical Outcomes in Pemphigoid Gestationis, Frontiers in Medicine 2020, 7:604945.
5. Rachel Seidel et al., Pemphigoid Gestationis: A Case Report and Review of Management, J Drugs Dermatol 2015 Aug;14(8):904-7.
6. Kar Sumit et al., Pregnancy and skin, The Journal of Obstetrics and Gynecology of India (May–June 2012) 62(3):268–275.
7. Kristina Semkova, Pemphigoid gestationis: current insights into pathogenesis and treatment, European Journal of Obstetrics & Gynecology and Reproductive Biology 145 (2009) 138–144.
8. Stephanie C. et al., Pemphigoid gestationis: a case series and review of the literature, Journal of Dermatological Treatment, 1471-1753.
9. Hai Ning Jiao et al., Diagnosis, fetal risk and treatment of pemphigoid gestationis in pregnancy: A case report, World J Clin Cases, December 6; 9(34): 10645-10651, 2021.
10. Christina M. Ambros-Rudolph, Dermatoses of Pregnancy - Clues to Diagnosis, Fetal Risk and Therapy, Ann Dermatol. 2011 Aug; 23(3): 265–275.
11. Chi CC et al., Pemphigoid gestationis: early onset and blister formation are associated with adverse pregnancy outcomes. Br J Dermatol. 2009;160(6):1222–1228.
12. Aoyama Y et al., Herpes gestationis in a mother and newborn: immunoclinical perspectives based on a weekly follow-up of the enzyme-linked immunosorbent assay index of a bullous pemphigoid antigen noncollagenous domain. Arch Dermatol. 2007.
13. Laura Huilajaet al., Gestational pemphigoid, Orphanet J Rare Dis. 2014; 9: 136.

Conflict of interest
NONE DECLARED

Correspondance address: Oana Mirela Tiucă
Physiopathology Discipline, "George Emil Palade" University of Medicine and Pharmacy, Sciences and Technology, Târgu Mureș, Romania
e-mail: oanaa.marginean@yahoo.com